

PATIENT PRESENTING CLINICAL SIGNS

Lizzy DeMarco

Grade II/VI left apical murmur. Coughing several times a day for years.

SPECIES ECHOCARDIOGRAPHIC FINDINGS

Canine

2D, M-mode, and Doppler study.

BREED

Pomeranian Mix

There is mild left atrial dilation. The mitral valve leaflets are mildly thickened and exhibit mild systolic prolapse. A mild to moderate jet of eccentric mitral regurgitation is present. There is mild left ventricular dilation. Left ventricular systolic function is hyperdynamic. The aorta and aortic are normal. Right atrial and right ventricular dimensions are normal. The tricuspid valve is normal. The pulmonary artery and pulmonic valve are normal. No heartworms are visualized. No pericardial effusion or cardiac masses are seen.

SEX

FS

LA - 40.1 mm
 LVIDd - 39.5 mm
 LVIDs - 19.2 mm
 FS - 51%
 RA - 23.6 mm
 LVOT - 1.72 m/s
 RVOT - 0.84 m/s

AGE

13 y

INTERPRETATION OF THE FINDINGS & FURTHER RECOMMENDATIONS

WEIGHT

28.8 lb

Degenerative mitral valve disease

INTERPRETED BY

Keith Blass, DVM, MS
DACVIM(Cardiology)

This examination demonstrates mild to moderate regurgitation of blood across Lizzy's mitral valve resulting from degenerative valve disease. Secondary to her regurgitation, Lizzy has mild dilation of both her left atrium and left ventricle, though her left ventricular systolic function is well-preserved. As only mild left heart chamber dilation is present, Lizzy's mitral valve disease appears to be relatively well-compensated, and it's unlikely that her disease is contributing to her cough.

Thoracic radiographs may be warranted to further evaluate Lizzy's cough.

HOSPITAL NAME

Mass Veterinary Services

I recommend starting Lizzy on pimobendan (5 mg am, 2.5 mg pm), as this medication should help to slow the progression of her mitral valve disease, as well as improve any potential cardiogenic contribution to her cough.

REFERRING VET

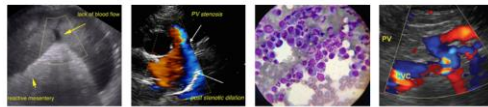
Dr. Masloski

A recheck echocardiogram is recommended in 9 months to monitor for disease progression.

INVOICE

DATE

12/15/21



PATIENT

Lizzy DeMarco

SPECIES

Canine

BREED

Pomeranian Mix

SEX

FS

AGE

13 y

WEIGHT

28.8 lb

INTERPRETED BY

Keith Blass, DVM, MS
 DACVIM(Cardiology)

HOSPITAL NAME

Mass Veterinary
 Services

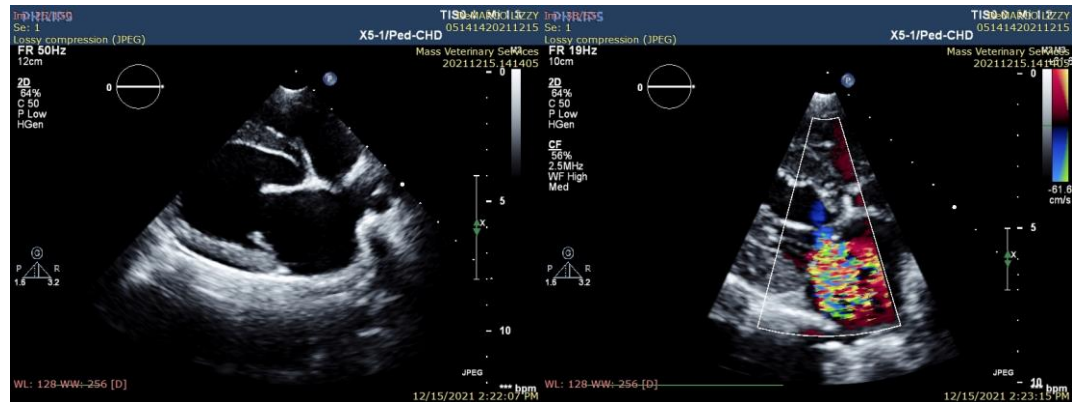REFERRING VET

Dr. Masloski

INVOICE

DATE

12/15/21



The information and recommendations provided are based on the images presented by the referring veterinarian. No evaluation can be communicated regarding pathology that was not visible in the image/video clips provided.

Thank you for this referral. If the clinical or image interpretation does not parallel your findings or if I can be of any further assistance please contact me.

Keith Blass, DVM, MS, DACVIM (Cardiology)

KeithBlass@gmail.com

631-804-5754